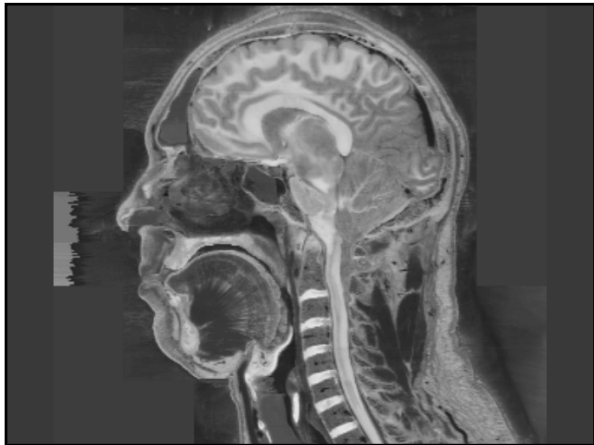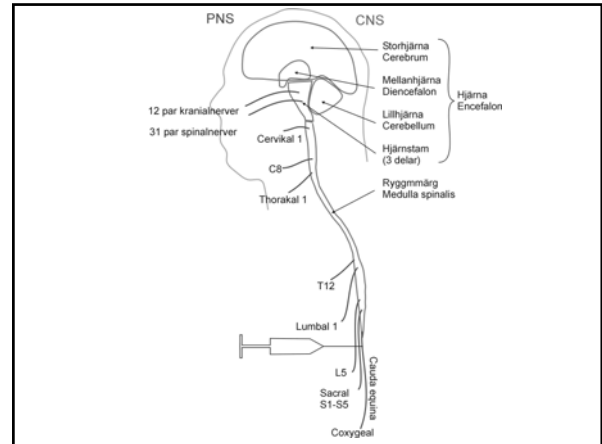
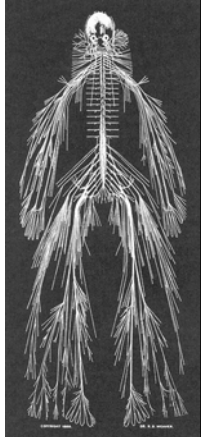
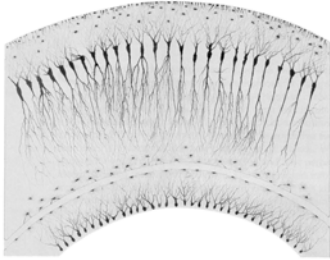
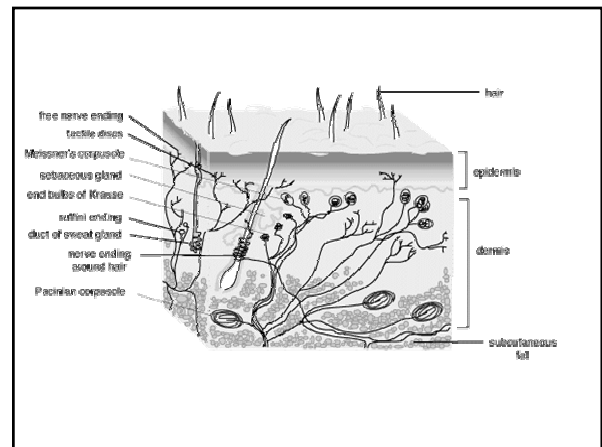
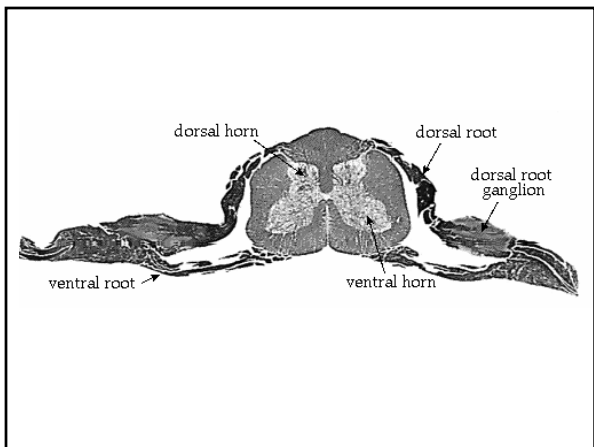

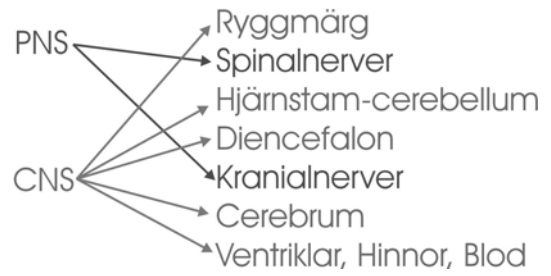
Nervsystemets anatomi
Karl Daggfeldt



Upplägg



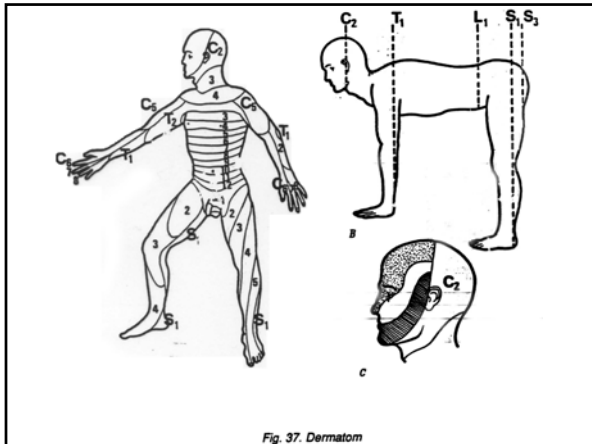
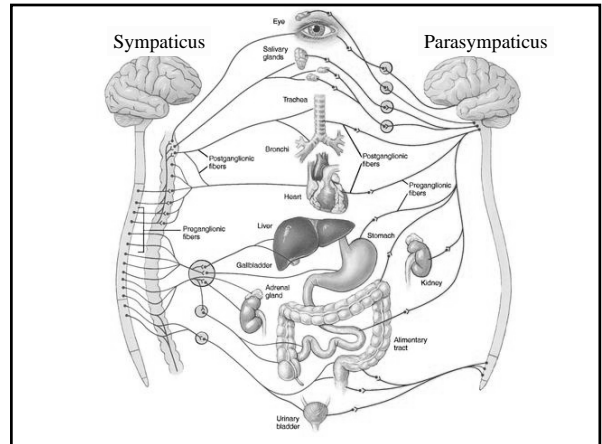
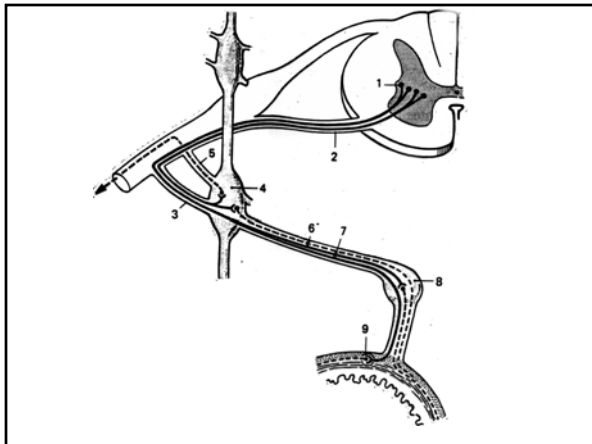
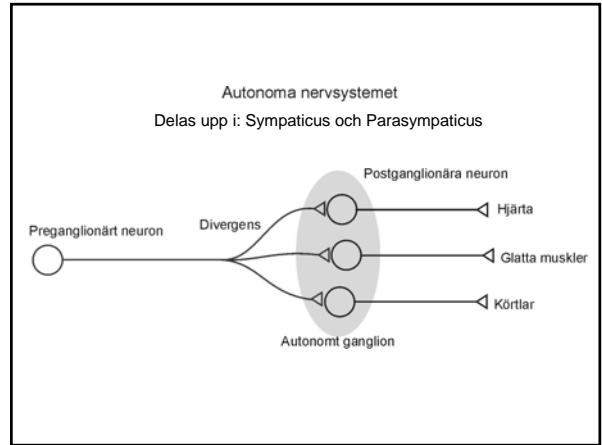
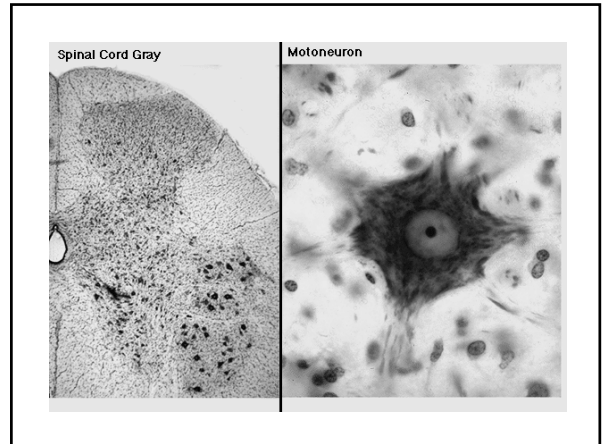
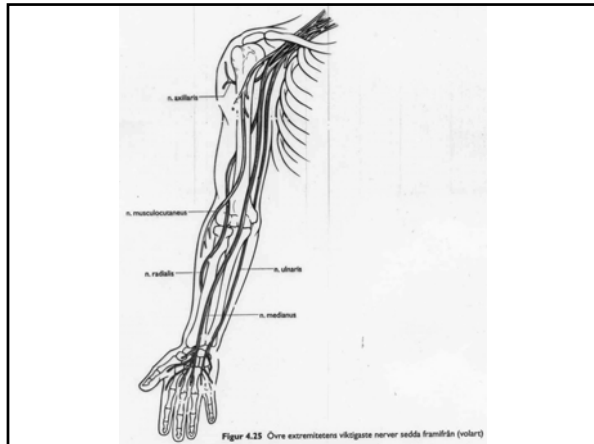


Fig. 37. Dermatome





Figur 4.25 Övre extremitätens viktigaste nerver södda framifrån (volant)

